Azad Jammu & Kashmir Medical College
Muzaffarabad

RESPIRATORY MODULE

1st Year MBBS 2017

Module Code: RES-0104
Duration: 4 Weeks
Starting on: May 8, 2017

DEPARTMENT OF MEDICAL EDUCATION

MODULE TEAM

Name	Role
Dr. Muhammad Ayub	Planner
Dr. Ijaz Anwar	Co-ordinator
Dr. Fauzia Aihtezaz	Member
Dr. Shakil Sadiq	Member
Dr. Zahid Azeem	Member
Dr. Babar Bilal	Member
Dr. Uzma Hafeez	Member

Rationale

Respiratory system is one of the most important systems of the body as it is responsible for oxygenation of blood and disposal of carbon dioxide from the body. This process of gaseous exchange called respiration must be understood by the student for comprehension of the mechanics involved in inspiration and expiration. There are different neural and humoral factors, which control the depth and frequency of respiration. The student will in clinical practice encounter patients with cyanosis, hypoxia, and peripheral and central edema hence the mechanism and its co-relation with respiration should be understood. Pakistan is a country with high prevalence of respiratory diseases particularly in children where the leading cause of morbidity and mortality in children is ARI and pneumonia. The students will come across during training and eventually in clinical practice the different types of respiratory failures. To combat the same the basis of oxygen administration and artificial ventilation should be taught in earlier years. The understanding of airflow dynamics will enable the student to understand the diseases like asthma, chronic bronchitis and their remedies. Asthma and allergic respiratory diseases are on the rise in Pakistan due to increasing pollution. At the same time the diseases related to smoking like lung cancer and chronic bronchitis are also on the rise and a firm understanding of the respiratory system will enable the student to prevent such life-style diseases through spreading relevant health education messages. The student training should also include mechanism and uses of inhalers. The ultimate goal of circulation is to carry the nutrients and oxygen to all the cells of the body and to carry the waste from the cells to the organ of disposal. One such waste is carbon dioxide. Oxygen and carbon dioxide are both gases and are exchanged in lungs, which carry out the process of respiration through the act of breathing. The student must be able to appreciate the mechanics involved in increasing and decreasing the intra thoracic volume and pressure changes accompanying it. The oxygen is carried by hemoglobin in the red blood cells, which combines with it and releases it when partial pressure is low.

Teaching Strategy

The content of this module will be delivered by a combination of different teaching strategies. These include small group discussions (SGD), large group interactive sessions (LGIS), demonstrations in dissection hall, laboratory practical and clinical skill sessions at skill lab. Group projects will be assessed at the end of the block.

Organization of Module

The module consists of 6 themes, each based on a real life situation. The module will employ different modes of instruction, briefly described below. Major emphasis will be on discussion, analysis and deductions; all by the students and guided by the faculty.

Content Delivery

Curriculum will be delivered through clinical case scenarios each covering a theme. Read the cases and the objectives of the theme which you are supposed to encounter next day, understand and explain the case to yourself and read the relevant information. Following learning/teaching strategies will be employed to discuss the cases:

Small Group Discussion

Part of the course content will be delivered in small group sessions. The case will be the centre around which learning will take place. Depending on the case you might be required to deduce objectives and learning issues or only learning issues. Every group will have a facilitator. The facilitator will be there to keep you on the track, giving you maximum liberty to discuss and achieve the objectives as a group. Small groups in some cases may be followed by a wrap-up session.

Large group

Large group instruction will be employed at times sparingly. Attend large group sessions with the following focus:

a. Identify important points
b. Ask questions of points not well understood in the text contact session
c. Measure your learning comprehension

Videos

Video demonstrations on history taking and clinical examination may be shown to give you an idea into the disease process, testing, and practical aspects of communication with the patients.

Hands-on Activities/Practical

Practical activities, linked with the case, will take place.

Laboratories

Attending scheduled laboratory/practicals is a must. You are expected to do spirometry, Blood Gas Analysis, Acid-Base status, Serum electrolytes, etc. besides histological structure of the Respiratory tract. Use your labs to correlate text structures to actual specimens in lab practice.

Self-Directed Learning, and Directed Self-Learning

A few SDLs and DSLs have been added in between to create an environment for you to search literature and aquire

information from different sources to meet the learning objectives.

Assessment

In this 4-week teaching activity, you will have surprise quizzes and short tests to be added to your Internal Assessment. A full-fledged formative assessment will be taken at the end of module. This will be followed by feedback on your performance in the exam.

TABLE OF SPECIFICATIONS

Theme	Weight%
Nasal Discharge	15%
Chest Pain	20%
Breathlessness	25%
Rusty sputum	25%
Acclimatization	5%
Cheyne-Stokes Breathing	10%

LEARNING OBJECTIVES

1. Nasal Discharge

- Illustrate the upper respiratory tract
- Demonstrate the morphological features of upper respiratory tract (nose, paranasal, sinuses, larynx and trachea) along with their blood supply, lymphatic drainage and innervations
- Correlate the developmental anomalies of upper respiratory tract with clinical presentations
- Illustrate the histological features of upper respiratory tract
- Identify nasal conches septum nasopharynx on cadaver/model/picture/imaging modalities, larynx, trachea and bronchi under microscope
- Interpret the respiratory role of nose in health and disease
- Interpret the role of sneeze reflex in health and disease
- Take history and perform clinical examination and counselling of a patient with chronic nasal obstruction

2. Chest trauma

- Demonstrate the morphological features of thoracic cage on cadaver/model/manikin/skeleton
- Differentiate typical and atypical ribs and thoracic vertebrae
- Illustrate a typical intercostals space and its clinical significance
- Revisit the development of thoracic cage in pre and postnatal life, highlighting its congenital anomalies
- Compare and contrast the structural and functional features of muscles of respiration
- Demonstrate the morphological features of diaphragm in correlation with the functions
- Discuss the alveolar and pleural pressure during work of breathing
- Correlate the tissue and airway resistance in the work of breathing
- Relate the developmental anomalies of diaphragm to its functional significance
- Demonstrate movements of thoracic cage on SP/peer
- Describe the mechanism of pulmonary oedema and pleural effusion
- Relate ABC with management of a patient with chest injury
- Enlist indications of tube thoracostomy

3. Breathlessness

- Demonstrate the gross anatomical features of lungs, and identify the Structures in the root of lung with the help of models and specimen
- Illustrate the histological features of alveoli and lungs
- Relate the development of lungs with congenital anomalies
- Define surface tension, compliance and dead space air and enlist conditions affecting compliance
- Draw and label Compliance Diagram
- Describe the function of Surfactant and its composition

- Describe the effects of dead space air on alveolar ventilation
- Define Spirometry
- Differentiate tidal volume and residual volume
- Define four pulmonary capacities & how they are calculated
- Define alveolar ventilation and list 3 factors that determine alveolar ventilation
- Describe functions of respiratory passage and cough reflex

4. Rusty Sputum

- Define partial pressure and list the difference in partial pressure of respiratory gases in alveolar and atmospheric air
- Draw and label six different layers of respiratory membrane
- Name four factors that affect the rate of gas diffusion through respiratory membrane
- Define the diffusion capacity and compare diffusion of O_2 with CO_2
- Define ventilation perfusion and draw oxy-haemoglobin dissociation curve
- Enumerate four factors that shift oxy-haemoglobin dissociation curve to right and left
- Enumerate three mechanisms of CO_2 transport in blood
- Define Haldane and Bohr's effect
- Compare the pulmonary and systemic circulation, listing main difference between them
- Describe blood flow through the lungs and its distribution in zone 1, 2 and 3
- Define *p*H of human body, its scale, value and importance in health and disease
- Define acid and base, weak and strong acid and base
- Define and enlist buffers and their mechanism of action
- Define acidosis and alkalosis and differentiate and interpret the findings of respiratory acidosis
- Revisit study of myoglobinemia (causes and manifestations)
- Identify normal structures in chest X-Ray
- Describe the effect of smoking and nicotine on body and specifically on lungs
- Perform public counselling against smoking

5. Acclimatization

- Define the phenomenon of acclimatization
- Relate the effect of partial pressure of oxygen at various altitude
- Compare and contrast the mechanism of Mountain sickness and pulmonary oedema
- Explain the Toxicity of individual gases and their effect
- Explain the diver's decompression sickness
- Describe the mechanism of nitrogen narcosis in deep sea diving
- Discuss the SCUBA diving and use of the apparatus

6. Cheyne-Strokes Breathing

- Enlist 3 groups of respiratory neurons and their functions
- Explain functions of ventral, dorsal apneustic and pneumotaxic centres on respiratory group of neurons
- Draw course of Herring-Breuer's inflation reflex
- Define chemo sensitive area and correlate the functions of peripheral and central chemoreceptors
- Enlist effect of CO_2 and H^+ on respiratory centre
- Enlist chemical and neural factors and their role in control of respiration during exercise
- Define Cheyne-Strokes Breathing and its causes

THEMES

Themes 1: Running Nose

Case History:
Akram, a 5-year-old child was brought by his mother to the OPD. He was suffering from fever, rhinorrhoea, sneezing, cough and sore throat for three days. He was unable to swallow liquids. On examination, his body temperature was 104 ºF, tonsils were enlarged and red. His Submandibular lymph nodes were palpable and tender. The blood picture showed leucocytosis. His elder brother also had a similar illness 10 days back.
On examination his nasal turbinate and nasal mucosa looked pale oedematous, swollen, with clear mucoidal discharge on the floor of the nose.

Themes 2: Breathlessness (Add Hazards of Smoking and Prevention)

Case History:

Fifty-year-old driver, smoker for the last 20 years is complaining of gradually increasing shortness of breath for the last three years along with half a cup full of greyish white sputum occasionally yellowish. His complaints are exacerbated during winter season.
On examination he looks plethoric, has yellowish staining of thumb and index finger on right hand. Accessory muscles of respiration are moving. There is central cyanosis and no leg oedema. Pulse is 88/minute, full volume BP is 130/80 mm of Hg and respiratory rate is 28 per minute.
Chest examination: Barrel shaped chest, apex beat not visible, Trachea central in position, JVP not raised, percussion hyper-resonant note, breath sounds prolonged expiratory with scattered rhonchi
Rest of the systemic examination is normal except loud P2
Investigations: Hb 18.8 Gm/dl, WCC 8,900/mm^3
Spirometry showed reduction in FEV_1 and FEV_1/FVC
Arterial blood gases showed reduction of Po_2 level to 80 mmHg, Pco_2 42 mm Hg, *p*H 7.35, an HCO_3^- 28 mEq/L
Chest X-Ray showed tubular heart, and normal sized lungs, Hyper-inflated lung field and flat diaphragm
Sputum culture showed No growth

Keywords: Dyspnoea, Cyanosis, Rhonchi, lung function tests, brnoncho-dilators

Themes 3: Rusty Sputum (Revise it for Occupational Medicine, Add Asbestosis)

Jamila, a 50-year-old housewife, develop shortness of breath and cough for last 2 years. Initially it was mild, she was able to do household work but progressively it has increased to an extent that now she can hardly go to washroom or change her clothes. A little activity produced annoying dry cough which was some time productive and breathlessness. She feel fatigued and tired most of the day, and lost 10 Kg weight for last 1 year. Her son brought her to local GP who started her on anti-TB medicine but no improvement. She is now brought to you.
On examination she was emaciated lady, SOB at rest, marked clubbing of hand, central and peripheral cyanosis and bilateral fine inspiratory crackles up to midzone.
Examination of pericardium there was loud P2 and right pericardial heave and she has bilateral pitting oedema at ankles. CBC showed Normocytic Normochromic anaemia, and CXR showed bilateral reticulonodular shadows with ground glass appearance involving lung bases

Pulmonary function tests showed markedly decreased diffusion capacity for carbon monoxide
FEV_1/FVC was 88%, Vital capacity is decreased
HRCT: Extensive lung fibrosis and honeycombing

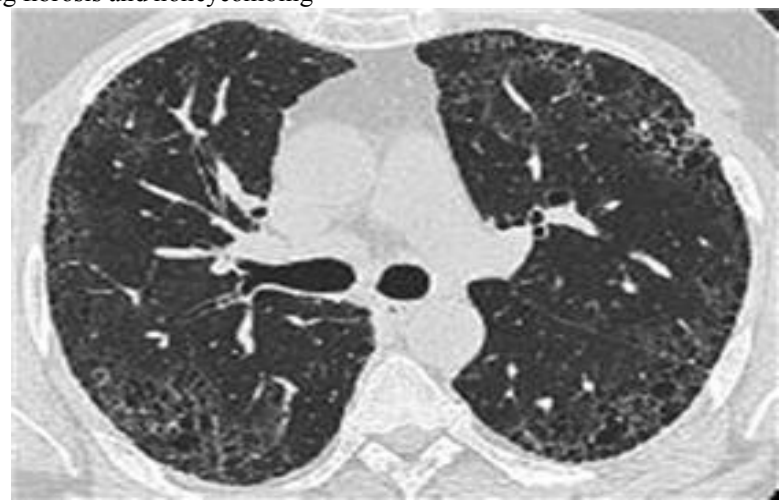

Keyword: Clubbing, Cyanosis, Fine Inspiratory Crackles, Reticulonodular Shadows

Themes 4: Chest Pain

A 48-year-old man presented in A&E AIMS with h/o assault 2 hours back.
He is complaining of left sided chest pain. There is no history of difficulty in breathing.
On examination, pulse: 90/min BP 120/80 mmHg Sao_2: 97%.
Chest examination: There is a bruise on the left side of chest. On palpation, there is tenderness in the left middle zone. On Auscultation, air entry is equal and good bilaterally. Routine blood investigations are normal. An X-ray chest was advised by trainee surgeon, which shows fracture left 5th rib.
Keyword: Palpation, Tenderness, Auscultation

Themes 5: Cheyne-Strokes Breathing

A 60-year-old local shopkeeper was doing his usual business at early morning when he suddenly felt severe headache and dizziness, his speech changed, he suddenly stood and fell down and become unconscious. He was brought to hospital by his friends and shifted to ICU. He didn't have any significant past illness apart from hypertension for which he was taking medicine.

Last 24 hours, his condition remains same, deeply unconscious. His CT scan brain done at ER was consistent with brain stem haemorrhage. House officer on duty, noticed that his breathing is irregular. He has progressively deeper and sometimes faster breathing, followed by a gradual decrease that results in a temporary stop in breathing. She noticed Cheyne-Stokes breathing in the patient due to haemorrhage compressing on brain Stem Respiratory Centre.

Keyword: Dizziness, Haemorrhage, Brain stem, Respiratory Centre

RECOMMENDED BOOKS

Snell's Clinical Anatomy by Regions
KLM Text book of clinically Oriented Anatomy
Textbook of Human Physiology (Guyton and Hall) 13th Edition or online
JB West: Respiratory Physiology, the Essentials, 4th Edition or later. Available online
Biochemistry – Lippincott's illustrated reviews (5th ed) (Champe, Harvey and Ferrier)
Mushtaq: Textbook of Biochemistry Vol I and II
Harper's Illustrated Biochemistry (Murray, Bender, Botham, Kennelly, Rodwell and Weil)
DiFore Atlas of Histology
The Developing Human: Clinically oriented Embryology (Moore and Persaud)
Textbook of Forensic Medicine and Toxicology by Parikh 6th Edition or
Risk factor and pollution www.who.int/gard/publications/risk%20factors.pdf
Tuberculosis literature from the WHO *www.who.int/gtb/publications/index.html*

Please note that the scenarios given to the class may not be the same as listed below. The development of the module and the scenarios is a continuous process and updated regularly.

PBL-1:

Akram, a 5-year-old child was brought by his mother to the OPD. He was suffering from fever, rhinorrhoea, sneezing, cough and sore throat for three days. On examination, his body temperature was 104 ºF, tonsils were enlarged and red. His jugulodigastric and submandibular lymph nodes were palpable and tender. The blood picture showed leucocytosis. His elder brother also had a similar illness 10 days back.
On examination his nasal turbinate and nasal mucosa looked red and oedematous, swollen, with clear mucoidal discharge on the floor of the nose.

Questions:

1. What is the problem with Akram?
2. What can be the probable cause of his problem?
3. How will you investigate him further?
4. How will you manage the case?
5. What will you advise to the mother and the family?

Raja Imtiaz, a 40-year-old man, smoker, married and living on a mountain in a remote village of Neelam Valley. He shares his two room house with wife, four children between ages of 5–15 years and his elderly father. He is a farmer and has sheep and goats. His mother died 10 years ago. He does not know the exact cause of her death.
For the last two months he has noticed weakness and tiredness and feeling of warmth in the evening. He feels better in the morning. For the last one month he has had cough initially dry but for the last few days it is an accompanied with yellowish-white sputum with slightly reddish colour. He think his also lose some weight.
He visited para-medical person in village who advised him to see a doctor at Basic Health Unit situated 5 Km away. He ignored the advice at his condition deteriorated with mark fever in the evening time increased cough with fresh blood in the sputum.
Finally he visited Basic Health Unit. The doctor examined him and referred him to District Headquarters Hospital for further tests. His blood and sputum test were performed, and also chest X-Ray done. He was started on medicines and strongly advised to take medicine regularly and come up follow up into weeks' time he was assured that his disease was treat able and he would get better. He continued his medicine for two months, felt well and his fever settled. He also felt energetic. He doctor did his chest x-ray and told him it was much improved and that he should continue his medicine for further four months.
He became irregular in taking medicine! His complaints recurred and his condition worsened. His started coughing with large amount of blood. One day he had sever episode of coughing and started coughing large amount of blood. He was taken to hospital. Treatment was started but he died two days later.

Chest Trauma

PBL-2

Abdul Rehman, aged 22 Years, came to Accident & Emergency of SKBZ-CMH with complaint of shortness of breath for the last 2 hours after he had a road traffic accident injuring his chest. He complained of chest pain and had shortness of breath since then. The patient was orthopnoeic which did not settle with rest or pain killers. It was also associated with one episode of blood stained vomiting.

Personal history: Driver by profession. Smoker since the age of 15 years. He belongs to lower middle class.

GPE: Young, thin, lean male lying on bed with irregular chest moments and rapid shallow breathing has following vitals: Pulse: 120 BPM, RR: 35/min, BP: 110/50 mmHg, Temp: 98 °F

Systemic Examination

CNS: Drowsy with GCS 14/15, Bilateral equal pupil responding to light, Spine intact, Muscle power 5/5, Sensations intact, Planters reflexes (Babinski's sign) down going.

Respiratory System:

Circular bruise on front of chest probably caused on hitting the steering wheel. Paradoxical chest movements on left side of chest. Absent breath sound upper and lower quadrants of left lungs. Dull percussion note on left side. Increased vocal resonance and vocal fremitus.

ABGs: *p*H: 7.56 Pco_2: 42 mmHg Po_2: 80 mmHg HCO_3^- : 28 mEq/L

RADIOGRAPHY:

X-ray chest AP Lat view showed fracture of neck of 2nd, 3rd, 4th and 5th rib at neck; 4th and 5th ribs are also fractured at their respective angles with haziness on left side.

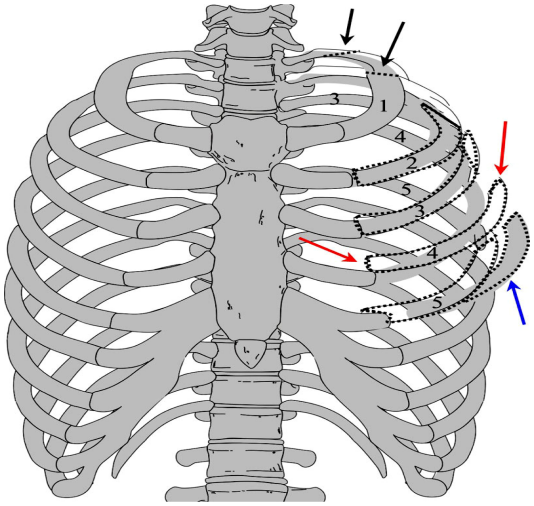

TIMETABLES

This is a tentative layout and distribution of the academic activities. The schedules may change as and when required to further strengthen the curricula and courses.

AJK Medical College, Muzaffarabad

RESPIRATORY Module

1st Year MBBS

Week-1					
Time	**Monday**	**Tuesday**	**Wednesday**	**Thursday**	**Friday**
8:00 –10:00 hrs	**Module Assessment LMR**	**Dissection** Upper respiratory track **Team 1**	**Dissection** Larynx and trachea **Team 1**	**Dissection** Thoracic cage **Team 1**	**Islamiat** **Pakistan Studies**
10:00 – 10:30 hrs	**Tea Break**				
10:30–11:30 hrs	**LGIS** Introduction to RES Module & PBL 1-A **Prof. Ayub & Module Team**	**LGIS** Development of upper respiratory tract **Prof. Shakil**	**Skill lab** History & examination of SP with nasal obstruction **Dr. Farooq Kayani & Dr. Naeem**	**SGD** Intercostals spaces & clinical correlates **Team-1 Wrap-up Dr. Asad Bilal**	**LGIS** Mechanics of Breathing Measurement of Dead Space and Residual Volume **Dr. AYUB**
11:30-12:30 hrs		**LGIS** Functions of Nasal Passages and vocalization **Dr Ijaz Anwar**			
12:30 to 1:30	**LGIS** Nose and paranasal sinus **Dr. Asad Bilal**	**DSL** Sneeze and Cough Reflexes and Process	**LGIS** Respiratory muscles **Dr. Asad Bilal**	**LGIS** Dead Space and Residual Volume **Dr. Ijaz Anwar**	**LGIS** Pleural Membrane and Pleural cavity **Dr Fauzia**
1:30-2:00 PM	**Lunch and prayer break**				
2:00 – 4:00 hrs	**Dissection** Upper respiratory track **Team 1**	**Practical** Histology of nose and paranasal sinus **Dr. Asma & Team 1**	**SGD** Ribs and vertebrae **Team 1** **Wrap up** **Dr. Asad Bilal**	**SGD** Gross Anatomy of pleura and diaphragm **Team 1**	**DSL** Composition of Air at various spaces of Respiratory Tract

AJK Medical College, Muzaffarabad

RESPIRATORY Module

1st Year MBBS

Week 2					
Time	**Monday**	**Tuesday**	**Wednesday**	**Thursday**	**Friday**
8:00-9:00 hrs	**Practical** A-Ana: Histology of Nose B-Phy: Examination of Thorax C-SDL: Pressures of Pulmonary system	**Practical** B-Ana: Histology of Nose C-Phy: Examination of Thorax A-SDL: Pressures of Pulmonary system	**Practical** C-Ana: Histology of Nose A-Phy: Examination of Thorax B-SDL: Pressures of Pulmonary system	**LGIS** Intercostal Spaces **Dr Shakil Sadiq**	**SGD** Respiratory Membrane **Dr. Ijaz and Team-2**
9:00 to 10:00				**LGIS** Pulmonary Circulation, Pulmonary congestion, oedema **Dr. Ijaz Anwar**	**LGIS** Carriage of Carbon dioxide, Heldane and Bohr's Effect **Prof. Ayub**
10:30-11:30 hrs	**Tea Break**			**Tea Break**	
10:30 to 11:30	**LGIS** Pharynx and Larynx **Dr. ASAD BILAL**	**PBL-2 A** **Dr ASAD BILAL and Team-1**	**LGIS** Development of Diaphragm Congenital anomalies of diaphragm **Dr Shakil Sadiq**	**SKILL LAB** Chest intubation **Dr Ziyad Kiyani, Dr Masood Kant, Dr Naheed**	**LGIS** Nervous and Chemical Control of Respiration **Dr Ayub**
11:30 to 12:30	**SGD** **Thoracic Cage** **Team-1**		**LGIS** Lung Volumes and Capacities **Dr AYUB**		
12:30 to 1:30		**LGIS** Thoraccic Cage **Dr Shakil Sadiq**	**LGIS** Oxyhemoglobin Dissociation Curve **Dr AYUB**	**Dissection** Pharynx & Larynx **Team-1**	
1:30 to 2:00					
2:00 to 3:00	**PBL-1 B** **Dr. Fauzia and Team-2**	**Dissection** Pharynx and Larynx **Team 1**	**Dissection** Larynx and Trachea **Team 1**	**SGD** Thoracic cage: structural and functional correlation **Dr. Asad & Team-1**	**DSL** **Hypoxia**
3:00 to 4:00					

AJK Medical College, Muzaffarabad

RESPIRATORY Module

1st Year MBBS

Week-3					
Time	**Monday**	**Tuesday**	**Wednesday**	**Thursday**	**Friday**
8:00–10:00	**Dissection** Diaphragm **Dr. Asad & Team** **LGIS** Pulmonary Function Tests **Dr. Ayub**	**Dissection** Lungs **Team-1**	**Symposium** **Recording and Analysis of a Forced Expiratory Spirogram** **Dr. Ayub, Dr. Ijaz**	**LGIS** Imaging of Thorax **Dr. Shaukat Dar** **LGIS** Development of Lungs **Dr Shakil**	**Skill Lab** Artificial Respiration CPR **Clinical Team from Anaesthesia Department SKBZ-CMH**
10:00–10:30	**Tea Break**				
10:30–12:30	**PBL–2B** **Dr ASAD & Team**	**LGIS** Body buffer system Acid base balance **Dr Zahid Azeem**	**LGIS** Respiratory insufficiency Hypoxia, Cyanosis **Prof. Ayub**	**Dissection** Lungs, lobes, fissures, Impressions, root of lungs & Bronchopulmonary segments **Team-1**	
1230–13:30	**LGIS** *p*H and buffers **Dr. Zahid Azeem**	**PBL–3A** **Dr Ijaz & Team**			
13:30-14:00	**Lunch & Prayers**				
2:00 to 4:00	**Practical** A: Spirometry, Interpretation of Normal Spirogram **Dr Hina and Team** B: *p*H estimation, ABG interpretation **Dr Nasim and Team** C: DSL: Pulse Oximetry	**Practical** B: Spirometry, Interpretation of Normal Spirogram **Dr Hina and Team** C: *p*H estimation, ABG interpretation **Dr Nasim and Team** A: DSL: Pulse Oximetry	**Practical** C: Spirometry, Interpretation of Normal Spirogram **Dr AYUB and Team** A: *p*H estimation, ABG interpretation **Dr Nasim and Team** B: DSL: Pulse Oximetry	**Sermon** *Istiqbaal e Ramadan*	**DSL** Tuberculosis and Respiratory Diseases

AJK Medical College, Muzaffarabad

RESPIRATORY Module

1st Year MBBS

Week 4					
Time	**Monday**	**Tuesday**	**Wednesday**	**Thursday**	**Friday**
8:00 – 9:90 hrs	**Skill lab** ABC of Chest Trauma Management and Thoracotomy **Dr. Shaukat Hayat,** **Dr. Raja Ijaz**	**LGIS** Acclimatization to High Altitude **Dr Ayub**	**LGIS** Deep Sea Diving **Dr. Ayub**	**Histology Slide Show** **Team-1**	**PBL–4 B** **Prof. Ayub & Team-2**
9:00–10:00 hrs 10:00-12:00	**PBL–3 B** **Prof. Ayub & Team-2**	**PBL–4A** **Dr. Ali Arshad & Team-2**	**LGIS** Special Problems of aviation and submarines **Dr. Ayub**	**Symposium** Prevention of Respiratory Diseases **Dr. Uzma Hafeez/Dr. Ayub, Dr. Alam Khan, Dr. Ijaz, Dr. Shakil, Dr. Fauzia, Dr. Zahid, Dr. Asad, and Team-1 and 2**	
		LGIS Occupational hazards to Respiratory System, Smoking **Brig. Dr. Ahmed Khan**	**Skill lab** History & exam of patient with Chest trauma **Drs. Farzana, Naheed, Masood**		
12:00 to 1:00	**LGIS** Physiological response of the body systems at high altitude **Dr Ayub**	**LGIS** Blood Gas Analysis **Dr. Zahid**			**JUMA PRAYERS**
1:30 to 2:00	**Prayers**				
2:00 to 3:00	**DSL** Occupational Health Hazards	**SDL** Special problems and Hazards of space flight	**DSL** Respirators and Mechanical Breathing	**Preparation of PBL**	**DSL** Self-Review of Respiratory Module

Inquires & trouble shooting

Department of Medical Education,
AJK Medical College, Muzaffarabad, AJK, Pakistan
Email: ayub@ajkmc.edu.pk, DME@ajkmc.edu.pk
Tel: +92-5822-920527-8/808, 816